



## Open Journal of Otolaryngology and Rhinology

Case Report

Open Access

### Cerebral venous thrombosis secondary to an occult maxillary sinusitis in a young male from sub-Saharan Africa

Mazou N Temgoua<sup>1\*</sup>, Mickael Essouma<sup>1</sup>, Larry N Tangie<sup>1</sup>, Cedric Tsinda<sup>1</sup>, Drusille Feze Foko<sup>2</sup> and Celestin Danwang<sup>3</sup>

<sup>1</sup>Departement of Internal medicine and specialties, Faculty of Medicine and Biomedical Sciences, University of Yaoundé I, Cameroon

<sup>2</sup>Internal Medicine Department, General Hospital of Yaoundé, Cameroon

<sup>3</sup>Departement of Surgery and specialties, Faculty of Medicine and Biomedical Sciences, University of Yaoundé I, Cameroon

**\*Corresponding Author:** Dr Temgoua Ngou Mazou, MD, MPH, Departement of Internal medicine and specialties, Faculty of Medicine and Biomedical Sciences, University of Yaoundé I, Yaoundé, Cameroun, Email: [neurotemgoua@yahoo.fr](mailto:neurotemgoua@yahoo.fr)

**Received Date:** Jan 09, 2019 / **Accepted Date:** Jan 21, 2019 / **Published Date:** Jan 22, 2019

#### Abstract

**Background:** Cerebral venous thrombosis (CVT), is a cerebrovascular disease characterized by an infarction of a cerebral vein. Only few cases have been reported. We report a rare case secondary to an occult maxillary sinusitis in a young male of Sub-sahar an Africa origin.

**Case presentation:** We report a case of a 36-year-old Cameroonian male who was admitted to hospital for left side hemiparesia associated with repetitive focal left-size tonicoclonic seizures and, frontal headache. The physical examination reveals normal vital signs, left cortical-type pyramidal syndrome, tactile hypoesthesia on the left side, normal ear nose throat examination. Cerebral magnetic resonance imaging (MRI) show a cerebral venous thrombosis and, a sinus radiograph revealed a right maxillary sinusitis, probably the etiology of the CVT. The patient was successfully managed by anticoagulant, antibiotics, maxillary sinus drainage and supportive measures.

**Conclusion:** CVT is a common cause of stroke in children and young adults. In sub-Saharan Africa, an infectious etiology should be considered and rollout before any other consideration.

**Keywords:** Cerebral venous thrombosis; Occult maxillary sinusitis; Case report

**Cite this article as:** Mazou NT, Mickael E, Larry NT, et al. 2019. Cerebral venous thrombosis secondary to an occult maxillary sinusitis in a young male from sub-Saharan Africa. Open J Otolaryngol Rhinol. 1: 08-12.

**Copyright:** This is an open-access article distributed under the terms of the Creative Commons Attribution License, which permits unrestricted use, distribution, and reproduction in any medium, provided the original author and source are credited. Copyright © 2019; Mazou NT

## Introduction

Cerebral venous thrombosis (CVT) also termed cerebral venous sinus thrombosis (CVST), is a special type of cerebrovascular disease characterized by cerebral venous infarction [1]. As from 1825 when the first case was described by Ribes [2], epidemiological descriptions are still restricted to case reports and small retrospective cross-sectional studies yielding low but increasing incidence: <10 cases per million per year in 1995 to about 13.2 cases per million per year in 2012. CVT mainly occurs in women of child bearing age, probably owing to the use of oral contraceptive pills, and mostly has an acute or subacute course [1]. It can be categorized as primary/idiopathic and secondary. Secondary CVT can further be classified into infective (mainly due to bacterial or fungal infections) and non-infective CVT; the latter being due to coagulation disorders, neoplasms, procoagulant hemodynamic states, vasculitis, homocystinuria, or head trauma [3]. With the advent of antibiotics, the epidemiology of CVT has shifted from predominant infective CVT to predominant non-infective CVT, leading to increased risk of misdiagnosis and delayed treatment [3]. We report occult purulent maxillary sinusitis-related CVT in a male Cameroonian patient who presented with headaches, seizures and acute stroke syndrome. The aim of this paper is to reiterate CVT as the main cause of acute stroke syndrome in young adults irrespective of ethnic origin and sex, and suggest systematic screening of infections in those patients, especially in regions with high rates of infections like sub-Saharan Africa. We describe this case with regard to CARE guidelines.

## Case presentation

A 36-year-old male patient with no contributive past history was admitted in a hospital for a rapidly progressive onset of left side deficit associated with repetitive focal left-side tonic clonic seizures lasting for 3 minutes and

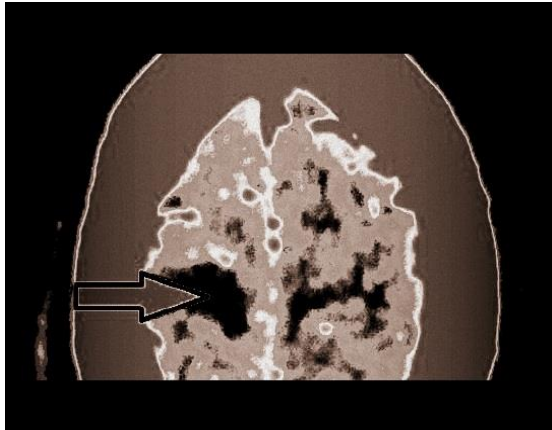
moderate intermittent frontal headache. These symptoms progressed since 24 hours before admission without fever or any other signs of intracranial hypertension.

Upon admission, physical examination revealed: normal vital parameters, left cortical-type pyramidal syndrome with brachio-facial predominance (muscular strength of 3/5 in the upper limb and 4/5 in lower limb), tactile hypoaesthesia in the left side, normal ENT examination.

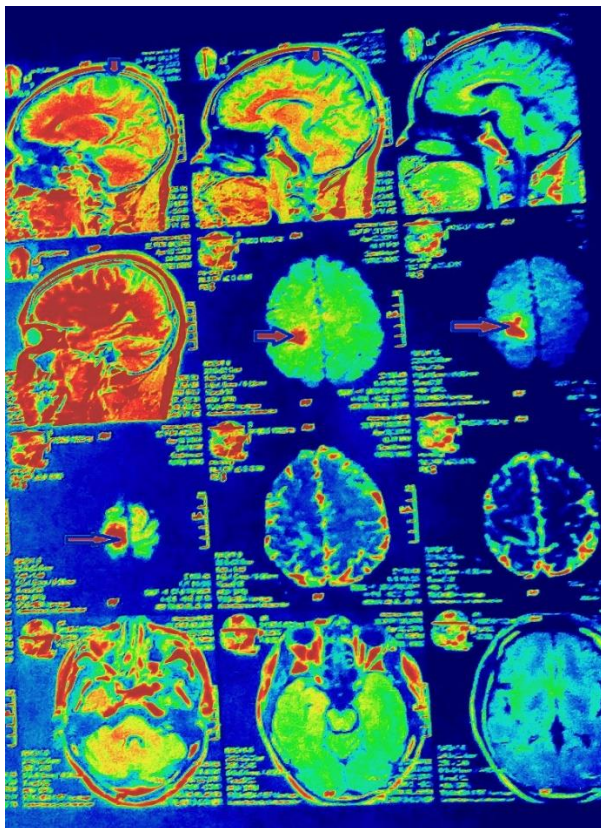
Based on this examination, we discussed a diagnosis of space occupying lesion or stroke. Cerebral CT-scan revealed a right fronto-parietal hypodensity which did not respect any vascular topography and this lesion was not enhanced with contrast (Figure 1). Subsequent cerebral magnetic resonance imaging (MRI) confirmed a cerebral venous thrombosis (Figure 2). On etiological work up, sinus radiograph revealed a right maxillary sinusitis (Figure 3). Biological exams showed a slight elevated white blood cells of 10 800 per mm<sup>3</sup> with neutrophils predominance at 81%. Prothrombin level=96.6% (international normalized ratio [INR] 1.3), Kaolin clotting time=27.5 s (witness time: 35 s), negative HIV serology, D-dimers=3886.61 ug per liter, C protein=117% and S protein=67%.

Finally, our working diagnosis was cerebral venous thrombosis secondary to a maxillary sinusitis. The patient was managed symptomatically by physiotherapy, analgesics paracetamol 3g per day, anticonvulsants diazepam: 20 mg per day. For the etiology drainage of maxillary sinus was done and the patient received 3g of amoxicillin and clavulanic acid per day. Acenocoumarol was used for anticoagulation at initial dose of 1mg per 24 hours, secondary adapted for International Normalized Ratio (INR) with a goal of 2-3, this goal was reached after 6 weeks of follow up (INR=2.17) with a daily dose of 5mg. The variation of INR through follow-up period can be observed in figure 4.

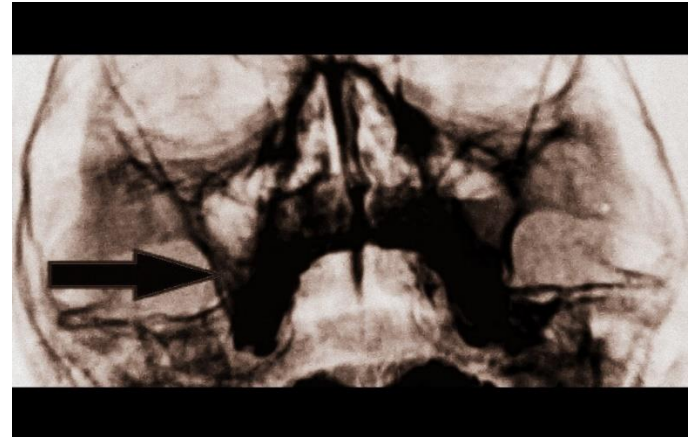
**Figure 1:** Cerebral CT-scan showing cerebral venous infarction.



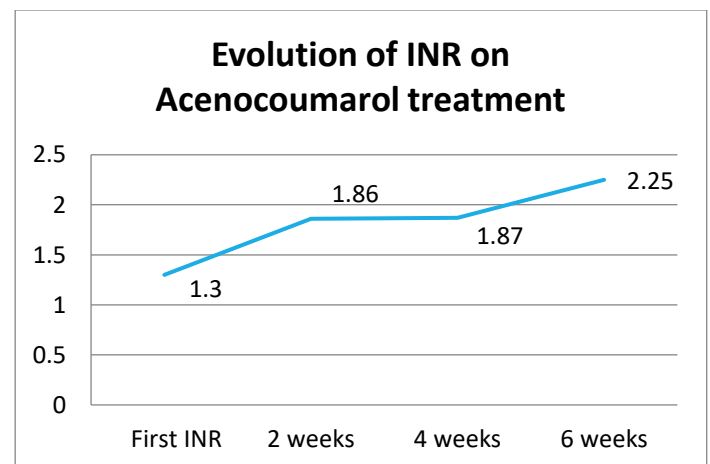
**Figure 2:** Cerebral MRI showing cerebral venous infarction.



**Figure 3:** Sinus radiograph showing right maxillary sinus abscess.



**Figure 4:** Evolution of INR on Acenocoumarol treatment.



## Discussion

This case describes a male patient with cerebral venous thrombosis (CVT) due to an inexpressive maxillary sinusitis. CVT is an acute or subacute disease of the central nervous system that often affects women of childbearing age, and children [1]. Its incidence varying between 1.32-1.57 per 100,000 person-years [4,5]. The disease is known more prevalent in women than men because of the high rate of contraceptive use that create a procoagulant status in this population [1]. Others risk factors

include coagulation disorders, neoplasms, vascularitis, homocystinuria, head trauma and infections [3]. In developed countries, this last condition becomes less frequent with the advent and adequate use of antibiotics [3].

Sinusitis is defined as infection of sinus; it's a common cause of infection related CVT [3]. The pathophysiology is directly by causing septic thrombosis or indirectly by precipitating thrombosis in people who have a prothrombotic condition; this is explained by cytokines inducing endothelial lesion. It's well known that the dural sinuses and the cerebral and emissary veins have no valves, which allow blood to flow in either direction according to pressure gradients in the vascular system. This makes these venous systems vulnerable to septic thrombosis resulting from spreading of infection from adjacent locations [3]. Maxillary sinusitis is rarely involved in CVT than sphenoidal and ethmoidal sinuses and clinical presentation associate facial pain, rhinorrhea and tenderness of the maxillary sinus [3,6]. Our patient was asymptomatic and it was difficult to clinically evoke this etiology. In the other hand the current diagnostic guidelines do not mention the systematic screening of CVT etiology by doing sinus radiography [7]. In the lack of evidence our approach was guided by the biological exam showing slightly elevated neutrophils which suggesting the bacterial etiology.

To the best of our knowledge, the association of occult sinusitis and CVT was not described in the literature, making this case an original one.

In Sub-Saharan African context with high burden of infection it may be necessary to systematically investigate sinusitis when any apparent cause of CVT is found.

## **Conclusion**

CVT is a common cause of stroke in children and young adults. In sub-Saharan Africa, and

infectious etiology should be considered and rollout before any other consideration.

## **Abbreviations**

CVT cerebral venous thrombosis; CVST cerebral venous sinus thrombosis; INR international normalized ratio; MRI magnetic resonance imaging

## **Declarations**

## **Acknowledgments**

The authors are solely responsible for this manuscript preparation and decision to submit it for publication.

## **Funding**

The authors declare that all data concerning this case report are provided within the manuscript.

## **Authors' contributions**

MNT, ME, LNT, CT, DFK, CD managed the patient. MNT drafted the initial manuscript which was modified by ME, LNT and CD. All authors read and approved the final manuscript.

## **Consent for publication**

Written informed consent was obtained from the patient for publication of this case report and any accompanying images. A copy of the written consent is available for review by the Editor-in-chief of this journal.

## **References**

1. Luo Y, Tian X, Wang X. 2018. Diagnosis and treatment of cerebral venous thrombosis: a review. *Front. Aging. Neurosci.* 10: 1-15. Ref.: <https://bit.ly/2AUa7j8>
2. Ribes M. Des recherches faites sur la phlébite. *Revue Médicale Française et Etrangère* et





## Cerebral venous thrombosis secondary to an occult maxillary sinusitis in a young male from sub-Saharan Africa

OJOR: Volume 1: Issue 1, January-2019: Page No: 08-12

---

Journal de Clinique de l'Hôtel-Dieu et de la charité de Paris. 3: 5-41.

3. Kojan S, Al-Jumah M. 2006. infection related cerebral venous thrombosis. J Pak Med Assoc. 56: 494-497. Ref.: <https://bit.ly/2FOELOo>
4. Coutinho JM, Zuurbier SM, Aramideh M, et al. 2012. The incidence of cerebral venous thrombosis: a cross-sectional study. Stroke. 3375-3377.
5. Devasagayam S, Wyatt B, Leyden J, et al. 2016. Cerebral Venous Sinus Thrombosis Incidence Is Higher Than Previously Thought: A Retrospective Population-Based Study. Stroke. 2180-2182. Ref.: <https://bit.ly/2HqBE1i>
6. Graham Worrall. 2011. Acute sinusitis. Can Fam Physician. 565-567. Ref.: <https://bit.ly/2U7nrtr>
7. Ferro JM, Boussier MG, Canhão P, et al. 2017. European Stroke Organization guideline for the diagnosis and treatment of cerebral venous thrombosis - endorsed by the European Academy of Neurology. Send to Eur J Neurol. 1203-1213. Ref.: <https://bit.ly/2AUnEaG>